

Anthrax: pathological aspects in autopsy cases in Shiraz, Islamic Republic of Iran, 1960–2001

S.Z. Tabei,¹ A. Amin, A. Mowla,¹ S.A. Nabavizadeh¹ and A. Razmkon¹

الجمرة الحبيثة: المظاهر الباثولوجية في حالات من فتح الجثث (الصفة التشريحية) في شيراز، إيران، 2001-1960

سيد صياء الدين نابعي، علي أمين، أشكان مولا، سيد علي أكبر نبوي زاده، علي رزمکن

الخلاصة: إن الجمرة الحبيثة تشبه السل من حيث عودة انتشارها من جديد في البلدان الصناعية، مما يظهر بعض الجوانب الغامضة في هذا المرض ويفرض تحديات على الطب. وقد سجلت جامعة شيراز ثلثون حالة من الجمرة الحبيثة (الصفة التشريحية) خلال السنوات الأربعين المنصرمة، كان من بينها 33 حالة بسبب الجمرة الحبيثة. وقد راجعنا جميع الشرائح الباثولوجية لهذه الحالات وصنفنا العضو المصاب بحثاً عن موجبات مجهرية لم يمكن التعرف عليها من قبل. وقد كان أكثر أسباب الموت شيوعاً الإلتان الناجم عن إصابة الأعضاء والتسمم الخلوي المباشر بالعصوات الحمرية وما تنتجه من ذيفان خارجي. ومن الملاحظات المصيدة تشكل أغشية هيالينية في حالات إصابة الجهاز التنفسي، وهذه الأغشية تشبه ما يحصل في متلازمة العمرة التنفسية الحادة لدى البالغين إلى جانب ببتات على إصابة بدنية في جهاز الهضم مما يوضح قدرة الجرثوم على عبور الحاجز المعدني.

ABSTRACT Anthrax, like tuberculosis, shows a new epidemic spread in industrialized countries, revealing some ambiguous aspects to the disease and providing new challenges to medicine. Shiraz University of Medical Sciences has records of 7130 autopsies performed in the past 40 years, 33 of which are anthrax cases. We reviewed all the pathology slides of these cases and classified the organs involved in a search for unrecognized microscopic findings. The most common cause of death was sepsis, caused by organ involvement and direct cytotoxicity of *Bacillus anthracis*, in addition to its exotoxin production. Novel findings included hyaline membrane formation in respiratory system cases that is similar to acute (adult) respiratory distress syndrome and evidence of primary gastrointestinal involvement, showing the ability of the organism to pass the gastric barrier.

Maladie du charbon : aspects pathologiques dans les cas d'autopsie à Chiraz (République islamique d'Iran), 1960-2001

RESUME A l'instar de la tuberculose, la maladie du charbon connaît une nouvelle poussée épidémique dans les pays industrialisés, révélant certains aspects ambigus de la maladie et posant de nouveaux défis à la médecine. L'Université des Sciences médicales de Chiraz a des dossiers de 7130 autopsies réalisées au cours des 40 dernières années, dont 33 concernent des cas de maladie du charbon. Nous avons examiné toutes les lames pathologiques de ces cas et avons classifié les organes atteints à la recherche de résultats de l'examen microscopique méconnus. La septicémie était la cause la plus courante de décès, due à l'envahissement des organes et à la cytotoxicité directe de *Bacillus anthracis*, en plus de sa production d'exotoxines. Les nouvelles découvertes comprenaient la formation de membrane hyaline dans les cas impliquant le système respiratoire qui est similaire au syndrome de détresse respiratoire aiguë (adulte) et l'évidence d'une atteinte gastro-intestinale primaire, révélant la capacité du micro-organisme à passer la barrière gastrique.

¹Department of Pathology, Shiraz University of Medical Sciences, Shiraz, Islamic Republic of Iran.

Received: 30/07/02; accepted: 09/01/03

Introduction

Anthrax, an acute infection caused by *Bacillus anthracis*, is acquired through contact with anthrax-infected domestic animals, or anthrax-contaminated animal products [1,2], and has the potential to be used in biological weapons [3,4]. While there is no clear evidence of direct human-to-human spread, the possibility has been discussed [5,6].

The disease is now extremely uncommon among humans but causes serious morbidity and mortality when encountered. The majority of descriptions of the pathology of anthrax date from the end of the nineteenth and beginning of the twentieth centuries. The preventive measures that were introduced at that time have almost eradicated the disease in some parts of the world and little attention has been paid to its epidemiology recently. Despite improved diagnostic and treatment techniques, anthrax, like other infections believed to have been eradicated, has emerged in a new epidemic that has gained worldwide attention [7,8]. This serves to remind us of our limited knowledge about the disease and the need for better early recognition and diagnosis that could result in more successful treatment of respiratory and gastric anthrax. It is worth noting that in current practice complete autopsy of confirmed (and even suspicious) cases of anthrax is no longer recommended, in order to decrease the risk of contagion [9].

As in other parts of the world, the number of anthrax cases in the Islamic Republic of Iran markedly decreased in the late twentieth century, but individual cases are still occasionally reported [10], especially among farmers and those who have direct contact with domestic animals or their products. The incidence of anthrax during

1996 was reported to be 0.54 per million population [11].

Shiraz University of Medical Sciences, founded in 1949, is a regional referral centre for all diseases and currently has an archive of about 7130 autopsy records from the last 40 years. Many of the anthrax cases have been presented earlier in the literature [12-14]. Our aim was to review the pathological findings in these autopsy records for unrecognized microscopic findings that could raise new concepts and to review the literature for theories about the pathogenesis of anthrax. We believe this would help improve diagnosis and treatment of the disease.

Methods

A review of records from the pathology ward of Shiraz University of Medical Sciences found 33 autopsies of anthrax cases performed between the years 1960-2001. All cases had been diagnosed by the clinico-pathological methods available at the time, such as Gram staining of fluids or tissues, different cultures and spore staining of the isolated organisms. All of the diagnoses had been confirmed by a complete autopsy, either through bacteriological investigations or the relevant organic histopathology findings.

The haematoxylin-cosin stained slides and special stains including tissue Gram stain were reviewed again to confirm previous findings and to look for new concepts. Cases were classified principally into cutaneous, pulmonary and gastrointestinal cases, according to light microscopy histopathology findings. Related findings in other organs were also considered. Then the data was analysed and reported, followed by a brief review of the literature.

Results

There was no significant gender bias among the 33 autopsy records: 16 (48.5%) were from males and 17 (51.5%) females. All patients were aged between 1 year and 65 years, with a mean age of 28.4 years old. Most (63.6%) were between 20–40 years of age. Thirty out of 33 patients had been living in rural areas, and were thus likely to have been in close contact with domestic animals.

Under light microscopy, 28 cases out of 33 (84.9%) had respiratory manifestations of anthrax (Figure 1). Most cases (26) had pulmonary congestion and haemorrhage with dilated interalveolar vessels and patchy parenchymal haemorrhage. Figures 2 and 3 show examples of marked exudation of serosanguinous fluid in the alveolar spaces, accompanied by intra-alveolar haemorrhage and mild fibrin deposition. Typical hyaline membrane formation was noted in 5 cases indicative of acute (adult) respiratory distress syndrome (ARDS). Leukocyte infiltration consisted mostly of neutrophils; just 1 case had prominent lym-

phoplasmacytic infiltration. The inflammation was intra-alveolar in 10 cases and interstitial in 6 cases. Five patients showed parenchymal necrosis and 5 cases hyperplasia of the alveolar wall and intra-alveolar haemosiderin-laden macrophages.

Only 3 of those who had pulmonary infection showed evidence of pleural involvement, in the form of effusion and leukocyte infiltration. Well-formed acute lobar or patchy pneumonia was scarce. Eleven cases (one-third of all cases) had evidence of upper airway involvement and inflammation: 1 case in this group had cutaneous anthrax of the neck without any evidence of septicemia or internal organ involvement, and died of asphyxia due to severe upper airways obstruction from oedema.

Cutaneous anthrax was seen in 23 out of 33 cases (69.7%) but was the cause of death for only 1 patient (mentioned above). Several cases of cutaneous anthrax in our series had been treated for insect bites before developing the characteristic skin lesion of anthrax (a coal-black, scar-forming lesion). Ulceration and necrosis of the skin

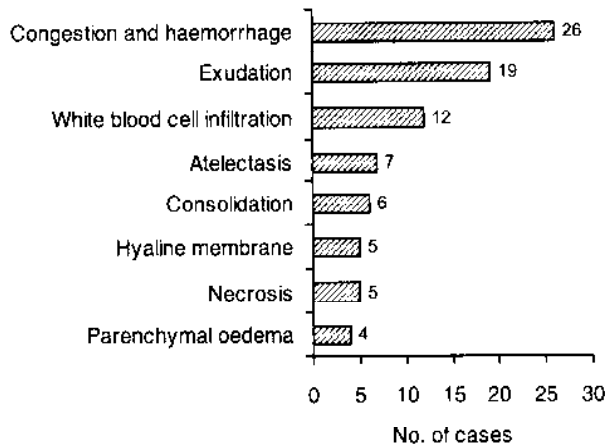


Figure 1 Histopathology findings in 28 autopsy cases with pulmonary anthrax

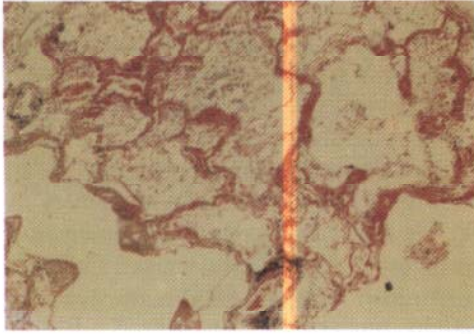


Figure 2 Low power view of acute respiratory distress syndrome in lung tissue. Note necrosis, congestion and inflammation with hyaline membrane formation in the alveolar tissue

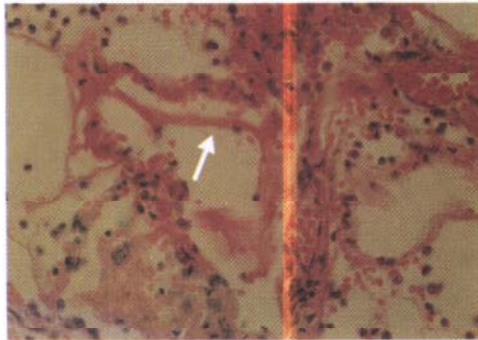


Figure 3 High power view of alveolar tissue, revealing the hyaline membranes (arrow)

was the most common finding (17 cases), involving all layers of the skin (Figure 4). Other typical histological findings were: oedema (15 cases), vascular congestion and haemorrhage (12) and white blood cell infiltration (8).

Twenty-two out of 33 cases (66.7%) had gastrointestinal manifestations of an-

commonly the small bowel (19 cases), the stomach (7 cases) and the large bowel (4 cases). The histopathology findings are summarized in Figure 5. Only 1 case had ascites, while 6 of them had evidence of peritoneal involvement, mostly in the form of oedema and leukocyte infiltration. Gastrointestinal involvement was the single cause of septicaemia and death in one-quarter of patients with gastrointestinal anthrax (15% of all cases), all of whom showed peritoneal involvement and a degree of haemorrhagic oedema (causing abdominal protrusion in a few cases) and leukocyte infiltration.

Lymphadenopathy was detected in 13 of the 33 cases (39.4%). The lymph nodes affected were adjacent to the organs involved: the mesenteric nodes in gastrointestinal cases and the cervical, axillary and parahilar nodes in pulmonary cases. Generalized lymphadenopathy was seen in a few cases. No specific histological changes were present in the slides. The most severe cases showed haemorrhagic lymphadenitis and necrosis, with extension to the adjacent mediastinum or mesentery. Congestion and neutrophil infiltration were more common. Bacilli were only rarely identified in the involved lymph nodes.

Splenic congestion was a major finding, evident in 17 cases (51.5%). Five patients showed various degrees of congestion and infiltration of acute and chronic inflammatory cells in areas of red pulps indicative of acute septic splenitis, and 3 patients (including the one with typhoid fever) showed splenic infarction. Significant splenomegaly was noted in 5 cases on autopsy.

Hepatic findings were noted in 17 cases (51.5%), mostly in the form of sinusoidal dilatation and congestion, mainly parenchymal and rarely subcapsular, producing hepatocellular necrosis in some areas, probably due to a pressure effect. Fourteen

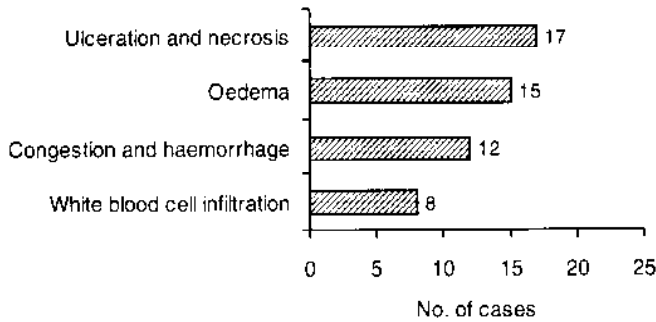


Figure 4 Histopathology findings in 23 autopsy cases with cutaneous anthrax

of these cases showed various degrees or parenchymal neutrophilic infiltration indicating hepatitis. Abscess formation was noted in 1 case.

Three out of 33 cases (9.1%) had histopathological findings of meningeal involvement showing mainly leptomeningeal congestion and neutrophile infiltration. One patient had a haematoma in the subarachnoid space.

Kidney findings consisted of congestion and intraparenchymal haemorrhage in 6 pa-

tients (18.2%) with signs of tubular necrosis in 3 of them.

The adrenal glands showed fat depletion and cortical tubular formation in 5 cases (15.2%) indicating septicaemia, and 3 cases showed congestion and haemorrhage of the adrenal parenchyma.

Bacillus anthracis was detected in 13 cases (39.4%) using haematoxylin-cosin or other special stains on the tissues. It is noteworthy that 1 of the cases was simultaneously seropositive for typhoid fever

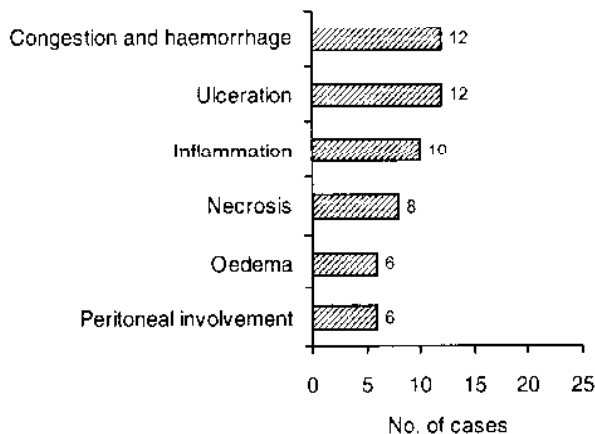


Figure 5 Histopathology findings in 22 autopsy cases with gastrointestinal anthrax

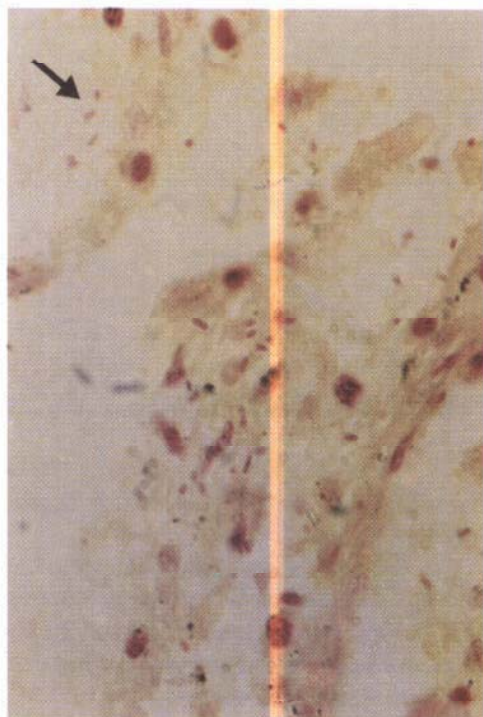


Figure 6 Anthrax bacilli inside a skin lesion (arrow). Note the spore-forming bacilli in a necrotic background

(both O and H antigen titres were about 1:320) with evidence of splenic haemorrhagic infarction and liver congestion. This patient died of anthrax septicaemia not typhoid fever.

Discussion

The causative agent of anthrax, *Bacillus anthracis*, is a large, non-motile, facultative and spore-forming Gram-positive rod (Figure 6). A glutamyl-polypeptide capsule is present that inhibits phagocytosis, and has a major role in the agent's pathogenic capabilities [15,16]. Anthrax toxin is well

known as the major toxic component of the bacillus, but non-virulent toxin-producing strains have also been isolated [15]. These mutant strains fail to produce the polyglutamic acid capsule.

According to the current classification of bacterial exotoxins, anthrax toxin has an AB pattern [17-20]. Two potent exotoxins, called 'oedema factor' and 'lethal factor' constitute the A domain which gains entry into the host cells by the B domain ('protective antigen'). Antibodies against protective antigen seem to confer immunity [16]. After entry, oedema factor produces tissue oedema through increasing adenylate cyclase activity [18,19]. It may also suppress neutrophil function [20,21], and hence leukocytes are rarely encountered in anthrax lesions regardless of the organs involved and the severity. Lethal factor has recently been shown to possess an endoprotease activity, interrupting a vital cell-signalling pathway that brings about direct cell death and cytokine production (including tumour necrosis factor- α and interleukin-1 β). It also inhibits mitogen-activated protein kinase (MAPK) and prevents cell proliferation [22-24].

Both the organism and its spore can be infective. The most common route of entry for anthrax is the skin (95% of cases). Other routes of entry are inhalation of airborne spores causing pulmonary anthrax (wool-sorter's disease) or ingestion of the organism or spores in contaminated food leading to gastrointestinal anthrax. The former is the most lethal type, killing 100% of the patients if untreated; the latter is the least common type but is also very dangerous.

Skin involvement in anthrax is characteristically painless but pruritic [25], which may be due to destruction of nerve endings in the affected areas of skin. Cutaneous manifestations are more prevalent in exposed areas of skin, most commonly on the head and neck [5]. Stings may play a role in

contagion, as some of the skin lesions begin as an insect bite [6,26]. Several cases of cutaneous anthrax in our series had been treated for insect bites before developing anthrax skin lesions. The most common histological findings of cutaneous anthrax consist of intense prolonged oedema, vascular congestion, haemorrhage and necrosis. Necrosis of the skin was the most common finding among our cases, involving all layers of the skin. The necrosis is mainly due to direct cytotoxicity of the organism [27] rather than ischaemia due to vascular compression caused by severe oedema. Cutaneous anthrax was recorded as the cause of death for only 1 patient, as death among cutaneous anthrax patients results mainly from the systemic dissemination of the disease [1,2,9,10].

In pulmonary anthrax, an acute alveolar or lobular pneumonia may develop, forming an extensive serofibrinous exudation throughout the parenchyma [28,29]; the striking characteristic of this pneumonia is the relative paucity of inflammatory cells. Haemorrhagic necrosis of the alveolar septum with a large number of bacteria may be present. Mucosal oedema may involve any level, from the oropharynx down to the alveoli. Acute mediastinitis and mediastinal widening due to lymphadenitis and haemorrhagic oedema in the mediastinum may be present. Occasionally, intravascular thrombosis may be a cause of death in respiratory anthrax [30].

In our series of patients, pulmonary congestion was the most common finding. Many of those with pulmonary involvement showed dilated interalveolar vessels and patchy parenchymal haemorrhage. Exudation of serosanguinous fluid in the alveolar spaces accompanied by intra-alveolar haemorrhage and fibrin deposition was characteristic of the early stages of ARDS, leading to hyaline membrane formation followed by respiratory failure. Typical hya-

line membranc formation was noted in 5 cases; the other patients died before the hyaline membrane could form (3–7 days). Short survival also explains the low frequency of parenchymal necrosis in these patients, since necrosis was found only in those who survived longer. Very few cases showed hyperplasia of the alveolar wall and intra-alveolar haemosiderin-laden macrophages. Well-formed acute lobar or patchy pneumonia was scarce in our cases.

Oedema of the upper respiratory airways may be caused by primary mucosal infection with bacilli [7], but there was evidence of secondary spread of oedema from the skin surface to the deeper soft tissues in 1 of our patients. As previously mentioned, this patient had cutaneous anthrax lesions on the neck and died from asphyxia caused by severe oedema of the soft tissue and upper airways. No sign of systemic involvement was evident in this patient.

The alimentary canal may be involved in anthrax primarily from the mouth down to the large bowel. It seems that the symptoms are caused by bacilli in the tonsils and the gut-associated lymphatic tissue [8], but light microscopy shows full thickness involvement of the gut. Although massive oedema and ulceration with vascular congestion and haemorrhage is mentioned in the literature, other gastrointestinal findings are not much discussed. However, ascites and involvement of mesentery have also been reported.

In our series, the most and least frequently involved gastrointestinal sites were the small and large bowel respectively; the most common was the duodenum, followed by the jejunum and the ileum. The rate of stomach involvement (7/21 cases) was higher than previously reported [8,31,32], revealing that the bacillus can survive the usual gastric defence mechanisms such as gastric acid secretion. This

finding, and the large number of cases where stomach manifestations of anthrax were associated with septicaemia and death, suggest primary gastrointestinal involvement in anthrax, which contradicts previous reports in the literature [7,8].

Hepatic involvement was detected in half of our cases, showing some non-specific leukocyte infiltration in the liver parenchyma. Only 1 patient had significant abscess formation accompanied by the presence of many bacilli in the liver parenchyma. Hepatocellular necrosis, if present, was focal and scant.

Histopathological findings in the spleen were mainly due to systemic infection in those patients with anthrax septicaemia; therefore, no definite conclusions can be drawn about splenic involvement. Various degrees of congestion and infiltration of acute and chronic inflammatory cells in areas of red pulps were indicative of acute septic splenitis. Five cases showed splenomegaly on autopsy but there was little correlation between spleen size and the pathology findings.

Lymph node involvement adjacent to the primary organ involved was present in nearly 40% of cases, with a few cases of generalized lymphadenopathy. In its most severe form, haemorrhagic lymphadenitis and necrosis were present, with extension to the adjacent mediastinum or mesentery; hence the signs of mediastinal widening in chest X-rays [33]. Congestion and neutrophil infiltration were more commonly found. Bacilli were rarely detectable in the involved lymph nodes (or other organs) and this might be due to antibiotic therapy before death. Besides, bacilli engulfed by inflammatory cells are more difficult to see. Some investigators recommend new immunostaining techniques to reveal the bacilli, particularly the intracellular ones [34,35].

Meningeal involvement was found in a few cases in the form of non-specific congestion (mainly) and leukocyte infiltration. One case had subarachnoid haemorrhage. A case of anthrax accompanied by subarachnoid haemorrhage has been mentioned in the literature [36].

The adrenal glands showed non-specific signs of septicaemia, congestion and haemorrhage and were rarely infected directly by the organism. Involvement of the kidneys was notably non-specific among our cases, showing congestion and haemorrhage of the parenchyma.

Nearly all cases died sometime after antibiotic treatment was started, so the rate of organism cultivation was low, since *Bacillus anthracis* was sensitive to most antibiotics current at the time [15,16]. It has been reported that culturing before 21 hours of antibiotic therapy yields the organism in nearly all patients [8].

Conclusion

Although there have been great advances in our knowledge about the pathogenesis of anthrax in recent years, more research is still needed. Our review of autopsy findings was consistent with previous experimental reports. However, we observed manifestations of anthrax in some organs not previously discussed, such as the spleen. The major findings were an ARDS-pattern of pulmonary involvement and a primary involvement of gastrointestinal tissue including the stomach.

Acknowledgements

We would like to thank Mrs Shahmanesh, Mr Zebarjadi, Mr Jabedarbashi and all others who helped us in performing the above study.

References

1. Wight DGF, Heard BE. The lung. In: Symmers WSC, ed. *Symmers' systemic pathology, Volume 1*, 2nd ed. Edinburgh, Churchill Livingstone, 1976:321.
2. Bacillus. In: Murray PR et al. *Medical microbiology*. St Louis, Mosby, 1990:180-4.
3. Inglesby TV et al. Anthrax as a biological weapon. Medical and public health management. *Journal of the American Medical Association*, 1999, 281(18): 1735-45.
4. Pile JC et al. Anthrax as a potential biological warfare agent. *Archives of internal medicine*, 1998, 158:429-34.
5. Aksaray N et al. Cutaneous anthrax. *Tropical and geographical medicine*, 1990, 42(2):168-71.
6. Singh R et al. Cutaneous anthrax, a report of ten cases. *Journal of the Association of Physicians of India*, 1992, 40(1): 46-9.
7. Siriceanathana T et al. Outbreak of oral-oropharyngeal anthrax: an unusual manifestation of human infection with *Bacillus anthracis*. *American journal of tropical medicine and hygiene*, 1984, 33(1):144-50.
8. Abramova FA, Grinberg LM. Pathology of anthrax sepsis according to materials of the infectious outbreak in 1979 in Sverdlovsk (microscopic changes). *Arkiv patologii*, 1993, 55(1): 18-26 [In Russian].
9. Bacterial pneumonia. In: Spencer H, ed. *Pathology of the lung, excluding pulmonary tuberculosis*. Oxford, Pergamon Press, 1968:134-7.
10. Anthrax. In: Saebi E, ed. *Infectious diseases in Iran*, 1st ed. Tehran, Olset, 1987: 649-70 [In Persian].
11. Anthrax. In: Karimi A et al, eds. *A report and treatment protocol of contagious diseases in Fars Province, Iran*, 1st ed. Tehran, Mostafavi, 1997:70-5 [In Persian].
12. Dutz W, Saidi F, Kohout E. Gastric anthrax with massive ascites. *Gut*, 1970, 11(4): 352-4.
13. Anonymous (case report). Clinical pathological exercise. Intestinal anthrax. *Pahlavi medical journal*, 1976, 7(1): 147-59.
14. Amadi S et al. Human anthrax in Iran. Report of 300 cases and review of literature. *Tropenmedizin und Parasitologie*, 1974, 25(1):96-104.
15. Aerobic or facultative spore-forming rods. In: Baron EJ, Peterson LR, Feingold SM, eds. *Bailey and Scott's diagnostic microbiology*, 9th ed. St Louis, Mosby, 1994:451-6.
16. Reisner BS, Woods GL. Medical bacteriology, anthrax. In: Henry JB, ed. *Clinical diagnosis and management by laboratory methods*, 20th ed. Philadelphia, WB Saunders, 2001:1099.
17. Finkelstein A. Channels formed in phospholipid bilayer membranes by diphtheria, tetanus, botulinum and anthrax toxin. *Journal of physiology*, 1990, 84:188-90.
18. Leppla SH. Production and purification of anthrax toxin. *Methods in enzymology*, 1988, 165:103-16.
19. Little SF, Ivins BE. Molecular pathogenesis of *Bacillus anthracis* infection. *Microbes and infection*, 1999, 1:131-9.
20. Duesbery NS, Vande-Woude GF. Anthrax toxins. *Cellular and molecular life sciences*, 1999, 55:1599-609.
21. Zaucha GM et al. The pathology of experimental anthrax in rabbits exposed by inhalation and subcutaneous inocu-

- lation. *Archives of pathology & laboratory medicine*, 1998, 122(11):982-92.
22. Duesbery NS et al. Proteolytic inactivation of MAP-kinase-kinase by anthrax lethal factor. *Science*, 1998, 280:734-7.
 23. Strauss E. New clue to how anthrax kills. *Science*, 1998, 280:676.
 24. Duesbery NS, Vande-Wonde GF. Anthrax lethal factor causes proteolytic inactivation of mitogen-activated protein kinase. *Journal of applied microbiology*, 1999, 87(2):289-93.
 25. Hopps HC. Anthrax. In: Anderson WSD, ed. *Anderson's pathology*. 4th ed. St Louis, Mosby, 1961:236-37.
 26. Smego RA, Gebrian B, Desmangels G. Cutaneous manifestations of anthrax in rural Haiti. *Clinical infectious diseases*, 1998, 26(1):97-102.
 27. Grinberg LM et al. Quantitative pathology of inhalational anthrax I: Quantitative microscopic findings. *Modern pathology*, 2001, 14(5):482-95.
 28. Daildorf FG, Kaufmann AF, Brachman PS. Woolsorters' disease, an experimental model. *Archives of pathology*, 1971, 92(6):418-26.
 29. Dixon TC et al. Anthrax. *New England journal of medicine*, 1999, 341:815.
 30. Daildorf FG, Beall FA. Capillary thrombosis as a cause of death in experimental anthrax. *Archives of pathology*, 1967, 83(2):154-61.
 31. Infectious diseases. In: Robbins SL, eds. *Pathology*, 3rd ed. Philadelphia, WB Saunders, 1967:332-3.
 32. Infectious diseases. In: Morehead RP, eds. *Human pathology*. New York, McGraw-Hill, 1965:373-4.
 33. Baillie L, Read TD. *Bacillus anthracis*, a bug with attitude! *Current opinion in microbiology*, 2001, 4(1):78-81.
 34. Fritz DL et al. Pathology of experimental inhalation anthrax in the rhesus monkey. *Laboratory investigation*, 1995, 73(5):691-702.
 35. Mallon E, Mckee PH. Extraordinary case report: cutaneous anthrax. *American journal of dermatopathology*, 1997, 19(1):79-82.
 36. Suffin SC, Carnes WH, Kaufmann AF. Inhalation anthrax in a home craftsman. *Human pathology*, 1978, 9(5):594-7.