

Role of mast cells and T-lymphocytes in pemphigus vulgaris: significance of CD44 and the c-kit gene product (CD117)

N.R. Ghaly,¹ O.A. Roshdy,¹ S.A. Nassar,¹ S.M. Hamad² and A.M. El-Shafei³

أهمية كل من CD44 والمنتج CD117 للعتيدة الجينية - C في إحداث الثَّفَاطَات في مرض الفقاع الشائع

نهلة غالي، أسامة رشدي، سامية نصار، سعيد حماد، عفاف الشافعي

الخلاصة: لم تتضح حتى الآن الآليات الجزيئية التي تقف خلف الفيزيولوجيا المرضية لمرض الفقاع الشائع. وقد هدفنا لكشف أهمية اكتشاف كيفية التعبير عن بعض المستضدات التي قد تكون ذات دور أساسي في هذه العملية ولإسئمة المستضدات CD44 و CD117 لدى المصابين بالفقاع الشائع والفعال. وقد شملت الدراسة 17 من مرضى الفقاع الشائع الفعال مقابل 19 من الشواهد الأصحاء الأسوياء. وقد أظهرت النتائج الكيميائية والمهستولوجية والمناعية تعبيراً صريحاً عن CD44 في 13 مريضاً و CD117 في 9 من المرضى الذين تشكلت لديهم نفاطات حديثة. وقد كانت قيم النسبة المئوية للـ CD44 في اللمفاويات النائية المحيطية أعلى بدرجة ملحوظة لدى المرضى مما هي عليه لدى الشواهد، باستعمال تعداد الخلايا الانسيابي، وإضافة إلى ذلك كان هناك ازدياد ملحوظ في الشكل الذواب من العتيدة - C في أمصال المرضى بالفقاع الشائع الفعال مقارنةً بما لدى الشواهد. ومن هنا فإن الأنظمة العلاجية التي تستهدف CD44 أو CD117 قد تساعد في تخفيض شدة العملية الالتهابية في مرض الفقاع الشائع الفعال. إلا أن هذه التغيرات قد تعكس الالتهاب بشكل عام أكثر من التفاعل النوعي في مرض الفقاع الشائع.

ABSTRACT Molecular mechanisms underlying the pathophysiology of pemphigus vulgaris are still not clear. We aimed to determine the significance of detecting expression of some antigens that might be pivotal to the process, namely CD44 and CD117, in patients with active pemphigus vulgaris. Seventeen patients with active pemphigus vulgaris and 19 normal healthy controls were included in the study. The immunohistochemical results showed prominent expression of CD44 in 13 of the patients and CD117 in 9 of the patients with new blister formation. CD44 percentage values in peripheral T-lymphocytes were significantly higher in patients than controls, as detected by flow cytometry. In addition, there was a significant increase in a soluble form of c-kit in sera of patients with active pemphigus vulgaris compared to controls.

Rôle des mastocytes et des lymphocytes T dans le pemphigus vulgaire : importance du CD44 et du produit du gène *c-kit* (CD117)

RÉSUMÉ Les mécanismes moléculaires impliqués dans de la pathophysiologie du pemphigus vulgaire ne sont toujours pas clairs. Notre objectif était de déterminer l'importance de la détection de l'expression de certains antigènes pouvant jouer un rôle essentiel dans le processus, à savoir le CD44 et le CD117, chez des patients atteints de pemphigus vulgaire actif. Dix-sept patients atteints de pemphigus vulgaire actif et 19 témoins sains ont été inclus dans l'étude. Les résultats immunohistochimiques ont montré un haut niveau d'expression de CD44 chez 13 des patients et de CD117 chez 9 des patients ayant une formation de bulles récente. Le pourcentage de CD44 dans les lymphocytes T périphériques était significativement plus élevé chez les patients que chez les témoins, comme détecté par la cytométrie en flux. En outre, il y avait une augmentation significative de la forme soluble du *c-kit* dans le sérum des patients atteints de pemphigus vulgaire actif par rapport aux témoins.

¹Department of Dermatology; ²Department of Clinical Pathology; ³Department of Pathology, University of Tanta, Tanta, Egypt (Correspondence to A.M. El-Shafei: blackandwhite47@yahoo.com).

Received: 18/03/04; accepted: 05/10/04

Introduction

Pemphigus vulgaris (PV) is a life-threatening blistering skin disease in which patients' autoantibodies are directed against desmosomal glycoproteins, resulting in the loss of keratinocyte cell–cell adhesion [1].

The CD44 family of cell surface glycoproteins is widely expressed in epithelial, mesothelial and haemopoietic tissues and is thought to function primarily as adhesion molecules, involved in cell–cell and cell matrix interactions and thought to take part in cell motility [2,3]. First identified in lymphocytes in 1982, they act as co-stimulatory molecules for T cells, leading to the induction of effector functions in these cells [4]. A relationship between activated or memory-effector lymphocyte populations and increased expression of family members of CD44 has been described and the importance of such CD44 expressing cells in the effector arm of the immune response *in vivo* has been reported [5]. This molecule is encoded by a single gene located on the short arm of chromosome 11 [6].

It is well known that the c-kit proto-oncogene codes for a type III tyrosine kinase receptor protein (CD117) that is structurally related to other transmembrane receptors. It is expressed in many tissues and cells and binds to stem cell factor [7]—c-kit/stem cell factor is involved in the development of several lineages of stem cells, such as germ cells, neural crest-derived melanocytes and haematopoietic precursor cells [8].

Moreover, c-kit/stem cell factor interaction induces mast cell adhesion to extracellular proteins differentiation, proliferation, migration and survival. It also activates mast cells to secrete its mediators – tumour necrosis factor α , protease, esterase, glycosaminoglycans and phosphogluconate dehydrogenase [9]. Thus, strong membrane reactivity for CD117 identified in mast cells

may be useful in the diagnosis of mast cell disorders and to shed a light on the role of mast cells in autoimmune diseases [7].

Little is known about molecular mechanisms affecting mast cell and T lymphocytes function in PV. Therefore, we aimed to explore possible factors controlling mast cells and T-lymphocytes during blister development through assessment of CD44 and CD117 by immunohistochemical methods in order to clarify the role of the infiltrating inflammatory cells in the pathomechanisms of acantholysis in PV. We also evaluated the circulating activity of these cells in the sera of patients with PV, using flow cytometry for CD44-positive peripheral blood lymphocytes and enzyme-linked immunosorbent assay (ELISA) for CD117.

Methods

Patients

We selected 17 patients clinically and histologically proven to be suffering from PV who were attending the outpatient clinic of the Department of Dermatology at Tanta University Hospital; 19 normal healthy individuals were recruited as a control group. All the patients had received no treatment in the previous 5 weeks and they were experiencing an eruption for the first time or an exacerbation due to interrupted regimen of therapy. From each patient, 10 mL of venous blood were withdrawn; 3 mL were centrifuged to separate the serum which was kept frozen for CD117 analysis by ELISA. The remaining 7 mL were put in heparinized tubes to separate peripheral blood lymphocytes, which were then analysed for CD44 monoclonal antibodies by flow cytometry. A skin biopsy from new blisters and from perilesional skin was taken for all patients; 6 of the controls also had a skin biopsy taken.

Immunohistochemistry

Paraffin sections of 4 mm thickness were deparaffinized in xylene and dehydrated in ethanol. The slides were incubated in methanol containing 0.03% hydrogen peroxidase at room temperature for 30 minutes to inactivate endogenous peroxidase and then rinsed in distilled water. The tissue sections were microwaved for antigen retrieval in a plastic Coplin jar filled with 0.01 M citrate buffer in distilled water (pH 6.0). The specimens were then rinsed with tris-buffered saline (TBS) and incubated for 60 minutes at room temperature with monoclonal mouse anti-human phagocyte glycoprotein-1 CD44 (Code No. M 7082). The antibody gives optimal staining when used at a dilution of 1:40-1:80. DAKO Envision System avidin peroxidase (DakoCytomation, Carpinteria, California) was used as the detection system. PAP (BioGenex, San Roman, California) was used as chromogen as well as substrate.

The intensities of the staining obtained with the CD44 were assessed semi-quantitatively by comparing the staining intensity of a given blister area with that in the same section or with that at stratum basal and stratum spinosum of the perilesional epidermis, which served as an internal standard. The scale applied ranged from zero (no staining detectable) to 3 (a staining intensity greater than that of the epidermis).

Flow cytometry for CD44 on T cells

Peripheral blood was collected in preservative-free heparin tubes and diluted 1:1 with phosphate buffered saline (PBS). Peripheral blood mononuclear cells (PBMCs) were isolated by Ficoll-Hypaque gradient centrifugation [16]. Then 106 PBMCs were incubated with 10 µL anti-CD3-PE (Becton Dickinson, USA) and 10µL anti-CD44-FITC (Becton Dickinson) for 30 minutes at

4 °C in the dark. Cells were washed twice with PBS followed by fixation of cells in 0.5 mL 2% paraformaldehyde in PBS. Cells were acquired and analysed using flow cytometry (Becton Dickinson). For a negative control, irrelevant isotype-matched dye conjugated antibodies were used to stain cells. The mononuclear cells were graded according to their typical forward and right-angle light scatter followed by their expression on a dot plot of anti-CD3 versus anti-CD44 fluorescence. The percentage of T cells expressing CD44 antigen was then calculated [11].

ELISA for CD 117

A human CD117 ELISA kit (Diaclone Research, France) was used for the *in vitro* quantitative determination of soluble stem cell factor receptor molecule (ssCD117) in human serum.

Results

Immunohistochemistry

Skin from the controls exhibited mild intensity especially in basal and intermediate epithelial cell layers (Figure 1). There was positive expression of CD44 in 13 out of 17 (76.5%) patients with PV. Some of the stromal cells and T-lymphocytes were distinctly positive for CD44. PV lesions had a higher positivity of CD44 expression, compared to perilesional and normal skin. The epidermis exhibited variability in CD44 staining as the strongest staining was observed in the lower layers of the blister (Figure 2). The distribution of CD44 staining in the perilesional skin was only slightly increased or resembled that of the normal epidermis (Figure 3).

Of 6 normal control specimens, 3 showed mild positive melanocytes in the basal epidermal layer and it was difficult to

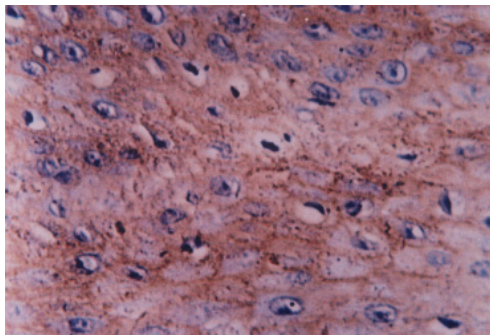


Figure 1 **CD 44 expression in the epidermis of normal skin showing mild membranous expression in stratum basale, stratum spinosum and part of stratum granulosum (PAP with haematoxylin counter stain × 400)**

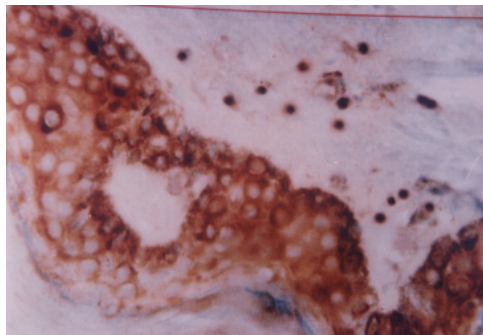


Figure 3 **CD 44 expression in the epidermis near the blister of pemphigus vulgaris showing mild membranous expression with positive lymphocytes and some stromal cells in the dermis (PAP with haematoxylin counter stain × 400)**

detect mast cells in these normal specimens (Figure 4). There was positive expression of CD117 in 9 of the 17 (52.9 %) patients with PV. Some of the stromal cells and mast cells were positive for CD117. PV lesions

had a higher positivity of CD117 expression (Figure 5), compared to perilesional skin. CD117 staining in the perilesional skin is illustrated in (Figure 6).

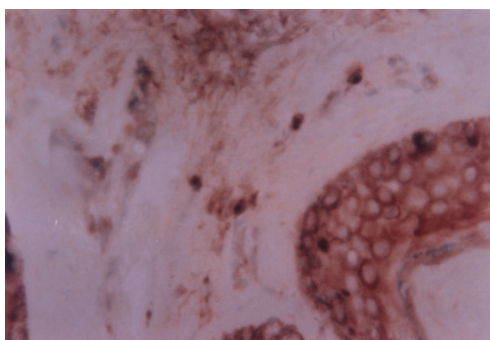


Figure 2 **CD 44 expression in the epidermis of pemphigus vulgaris showing strong membranous expression in stratum basale, stratum spinosum and part of stratum granulosum with positive lymphocytes in the dermis (PAP with haematoxylin counter stain × 400)**

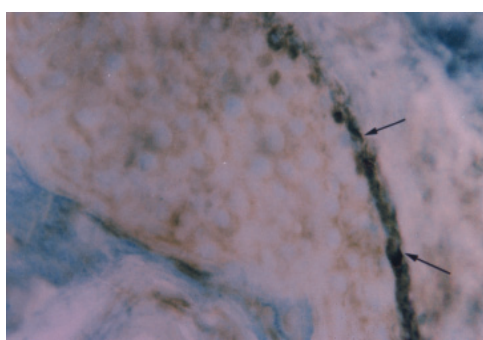


Figure 4 **CD117 expression in the epidermis of normal skin showing mild membranous and cytoplasmic expression of some melanocytes in stratum basale (PAP with light green counter stain × 400)**

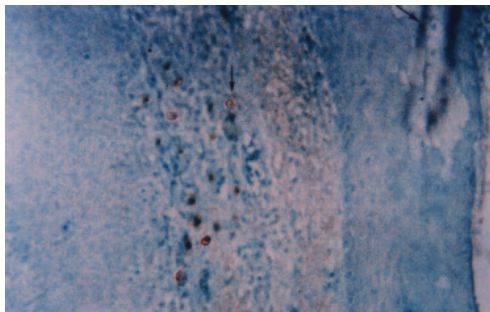


Figure 5 CD117 expression in the dermis of pemphigus vulgaris skin (arrow near the blister) showing strong membranous and cytoplasmic expression of some mast cells (arrow) (PAP with light green counter stain $\times 250$)

Flow cytometry (CD44)

There was a significant increase in the percentages of total lymphocytes (CD3) expressing CD44 in the patient group with active PV compared to the control group. The mean in the control group was 8%–15% while in patients with PV it was 12%–23% (Table 1, Figures 7 and 8).

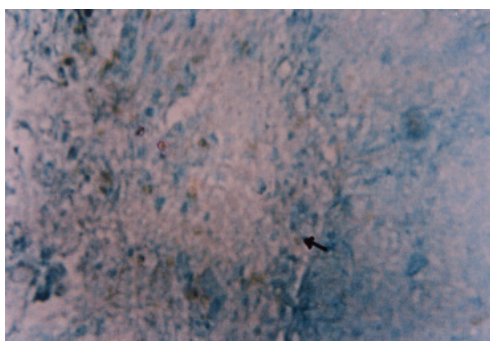


Figure 6 CD117 expression in the perilesional skin of pemphigus vulgaris showing mild membranous and cytoplasmic expression of some mast cells (arrow) (PAP with light green counter stain 250)

Table 1 Percentage of CD44 in peripheral blood CD3 in patients with pemphigus vulgaris and the control group

	Control group (n = 19)	Pemphigus vulgaris patients (n = 17)
Range	8%–15%	12%–23%
Mean (SD)	10.68% (2.45)	17.29% (4.25)
	$t = 5.65, P < 0.05$	

SD = standard deviation.

ELISA (CD117)

There was a significant difference between patients and controls ($P < 0.5$) for expression of CD117 (Table 2).

Discussion

Although there has been wide interest in the role of humoral immunity and autoantibodies in the pathogenesis of PV, the role of the cellular immune system is still unclear.

In the present study, CD44 expression was detected as an intense stain on the cell membrane of epidermal keratinocytes and some lymphocytes in the papillary dermis in active PV lesions. At the same time, nearby skin sections showed moderate positive staining. Normal skin, on the other hand, showed weak to negative staining for CD44. This concurs with Hashimoto et al. who detected positive CD44 acantholytic cells in PV [12]. This overexpression of the cell adhesion molecule CD44 in the epidermis of active PV could be explained by increased proinflammatory cytokines IL-1 alpha and TNF-alpha in an attempt to restore adhesive function between keratinocytes [13,14]. Therefore this finding might be considered a result of acantholysis and not an initiating event in this process [12,14]

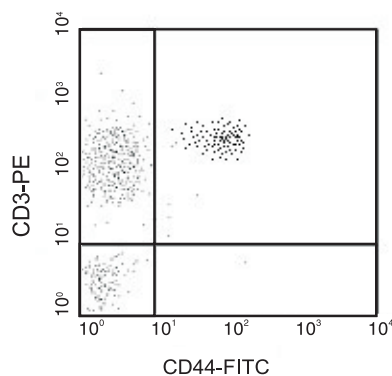


Figure 7 Total lymphocytes (CD3) expressing CD44 in normal controls

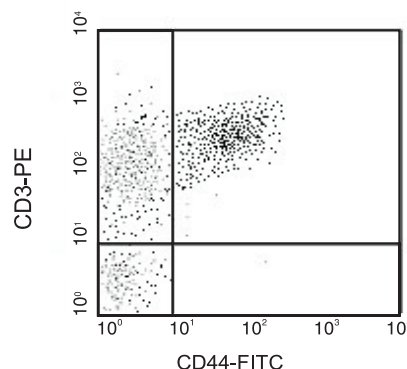


Figure 8 Total lymphocytes (CD3) expressing CD44 in patients with pemphigus vulgaris

Moreover, many authors have demonstrated a predominant expression of CD44 on skin-infiltrating lymphocytes that indicate adhesion to inflamed dermal microvascular endothelial cells as well as keratinocytes, an important prerequisite for the development of cutaneous inflammatory and immunological diseases [2, 15–17]. This finding was recently supported by the use of CD44 as a marker to evaluate activated T lymphocytes [15, 18]. The presence and role of activated T lymphocytes in this study is supported by Mashkilleyson et al. who demonstrated the release of IL2 R at the site of blister formation as an indicator for ac-

tivated T lymphocytes [19]. This increased CD44 on lymphocytes infiltrating the skin in active PV could explain the mechanism of lymphocyte activation, with these activated T cells serving as the trigger for a cascade of events that lead to the amplification of the inflammatory process with the resultant tissue damage at target sites [11, 16].

In our study, there was significant increased percentages of CD44 expressed on total T-lymphocytes by flow cytometry in the peripheral blood of patients with active PV. This is in agreement with other studies demonstrating that CD44 expressing

Table 2 Serum c-kit receptor level in patients with pemphigus vulgaris and the control group

	Control group (n = 19)	Pemphigus vulgaris patients (n = 17)
Range	30–58 ng/mL	42–130 ng/mL
Mean (SD)	40.16 ng/mL (8.23)	85.41 ng/mL (26.32)

$$t = 6.75, P < 0.05$$

SD = standard deviation.

cells correlate with autoimmune conditions [11,15]. In addition, Yang et al. reported that assessment of the expression patterns of surface antigen CD44 on peripheral blood T lymphocytes (using monoclonal antibodies directed against surface antigen by flow cytometry) is sensitive, safe, easily repeatable and controllable, and therefore can be considered a promising tool for the diagnosis of autoimmune diseases such as PV [15]. Therefore, it can be regarded more useful as a screening test or follow-up indicator rather than as an early diagnostic tool. Furthermore, indirect clinical evidence also supports the idea that T-cells may be involved in helping autoantibody production in PV [20].

It is a well known fact that mast cells are the key cells in allergic reactions and have a pivotal role in inflammation. However, the role of mast cells in blister formation of PV is still unclear.

The c-kit gene product (CD117), which is known to be expressed on tissue-anchored stromal cells, plays an important role in the development of c-kit bearing cells such as mast cells and melanocytes. In the present study, prominent membranous expression of CD117 in dermal mast cells was detected in active lesions, in contrast to the slight expression in perilesional skin. This finding supports the role of mast cells in blister formation and agrees with Caproni et al. who consistently detected granulocytes and mast cells that showed clear signs of activation in lesional skin of PV [20]. In addition, Kaminska et al. detected significant alterations in mast cell chymase and protease inhibitors in PV, suggesting mast-mast cell involvement in this bullous diseases [21].

Our study demonstrates that c-KIT is significantly elevated in the serum of patients with active PV compared with healthy controls. A similar significant relation between CD117 and disease activity has been detected in other autoimmune diseases such as psoriasis and systemic lupus erythematosus [20,22]. Therefore, assessment of the level of this marker provides valuable information of the probable severity of the condition. Its mechanism of action could be explained on the basis that mast cells contain large amounts of different proteolytic enzymes that can participate in cutaneous inflammation [23]. Moreover, mast cells could be involved in blister formation since elevated tryptic activity is formed in blister fluid of patients with PV [24]. Tryptase can activate single-chain urinary type plasminogen activator (pro-urokinase) which in turn could activate plasminogen to plasmin resulting in acantholysis [14,21]. Tryptases induce and maintain blister formation by continuous activation of collagenolytic metalloproteinases and degradation of fibronectin [14,25].

We conclude that therapeutic regimens targeting CD44 or CD117 might help ameliorate the inflammatory process in active PV. However, all these alterations could reflect general inflammation rather than a specific reaction in PV. Further studies are necessary to define the precise nature of acantholysis and molecular factors controlling mast cells and autoreactive lymphocytes at the genetic level to elucidate the primary event in the pathogenesis of PV with the aim of devising new strategies for better therapeutic intervention.

References

1. Jamora MJ, Jiao D, Bystryjn JC. Antibodies to desmoglein 1 and 3, and the clinical phenotype of pemphigus vulgaris. *Journal of the American Academy of Dermatology*, 2003, 48(6):976–7.
2. Johnson P et al. A role for the cell adhesion molecule CD44 and sulfation in leukocyte-endothelial cell adhesion during an inflammatory response? *Biochemical pharmacology*, 2000, 59(5):455–65.
3. Borland O, Ross JA, Guy K. Forms and functions of CD44. *Immunology*, 1998, 93: 139–48.
4. Trowhridge L et al. Biochemical characterization and cellular distribution of a polymorphic, murine cell- surface glycoprotein expressed in lymphoid tissues. *Immunogenetics*, 1982, 15:299–312.
5. Ariel A et al. Induction of interactions between CD44 and hyaluronic acid by a short exposure of human T cells to diverse pro-inflammatory mediators. *Immunology*, 2000, 100(3):345–51.
6. Brown TA et al. Human keratinocytes express a new CD44 core protein (CD44E) as a heparan-sulphate intrinsic membrane proteoglycan with additional exons. *Journal of cell biology*, 1991, 113:207–21.
7. Arber D, Tamayo R, Weiss L. Paraffin section detection of the c-kit gene product (CD117) in human tissues: Value in the diagnosis of mast cell disorders. *Human pathology*, 1998, 28:498–504.
8. Natali P et al. Expression of c-kit receptor in normal and transformed human lymphoid tissues. *Cancer research*, 1992, 52:6139–43.
9. Akin C et al. Soluble stem cell factor receptor (CD117) and IL-2 receptor alpha chain (CD25) levels in the plasma of patients with mastocytosis: relationships to disease severity and bone marrow pathology. *Blood*, 2000, 96(4):1267–73.
10. Ichikawa T et al. Expression of moesin and its associated molecule CD44 in epithelial skin tumors. *Journal of cutaneous pathology*, 1998, 25:237–43.
11. Estess P et al. Functional activation of lymphocyte CD44 in peripheral blood is a marker of autoimmune disease activity. *Journal of clinical investigation*, 1998, 102:1173–82.
12. Hashimoto K et al. Junctional proteins of keratinocytes in Grover's disease, Hailey-Hailey's disease and Darier's disease. *Journal of dermatology*, 1995, 22(3): 159–70.
13. Fitzgerald KA, O'Neill LA. Characterization of CD44 induction by IL-1: a critical role for Egr-1. *Journal of immunology*, 1999, 162(8):4920–7.
14. Feliciani C et al. Urokinase plasminogen activator mRNA is induced by IL-1 alpha and TNF-alpha in *in vitro* acantholysis. *Experimental dermatology*, 2003, 12(4): 466–71.
15. Yang J et al. The expression patterns of CD44 and CD45RB on peripheral blood T lymphocytes in the rejection of allogeneic murine skin transplantation. *Transplant immunology*, 2003, 11(2):197–206.
16. Pure E, Cuff CA. A crucial role for CD44 in inflammation. *Trends in molecular medicine*, 2001, 7(5):213–21.
17. Yasuda M et al. CD44: functional relevance to inflammation and malignancy. *Histology and histopathology*, 2002, 17(3):945–50.
18. Termeer C et al. Targeting dendritic cells with CD44 monoclonal antibodies selectively inhibits the proliferation of naive

- CD4+ T-helper cells by induction of FAS-independent T-cell apoptosis. *Immunology*, 2003, 109(1):32–40.
19. Mash N, Kauumen T, Visa R. Local involvement of antigen presenting cells and activated T cell in perilesional skin in pemphigus vulgaris. *Acta dermato-venereologica*, 1989, 69:424.
20. Caproni B et al. Further support for a role for Th2-like cytokines in blister formation of pemphigus. *Clinical immunology*, 2001, 98(2):264–71.
21. Kaminska R et al. Mast cell in developing subepidermal bullous diseases: Emphasis on tryptase, chymase and protease inhibitors. *Acta dermato-venereologica*, 1999, 79(5):351–5.
22. Yamamoto T, Katayama I, Nishioka K. Possible contribution of stem cell factor in psoriasis vulgaris. *Journal of dermatological science*, 2000, 24(3):171–6.
23. Kitoh T et al. Significance of stem cell factor and soluble KIT in patients with systemic lupus erythematosus. *Clinical rheumatology*, 1998, 17(4):293–300.
24. Levi-Schaer F et al. Increased numbers of mast cells in pemphigus vulgaris skin lesions: a histochemical study. *Acta dermato-venereologica*, 1991, 71: 269–71.
25. Lohi J, Harvima I, Keshi-Oja J. Pericellular substrates of human mast cell tryptase; 72 000 dalton gelatinase and fibronectin. *Journal of cellular biochemistry*, 1992, 50:337–49.
26. DeGrendele HC et al. CD44 activation and associated primary adhesion is inducible via T cell receptor stimulation. *Journal of immunology*, 1997, 159:2549–53.